

# A meta-analysis of the efficacy and safety of managing parotid and submandibular sialoliths using sialendoscopy assisted surgery

Fatima M. Jadu, BDS, PhD, Ahmed M. Jan, BDS, PhD.

### ABSTRACT

**الأهداف:** يستعرض هذا المقال خيارات العلاج المتاحة مع التركيز على فعالية وسلامة الجمع بين تقنيات المحافظة على الغدد اللعابية للحصول على أفضل النتائج.

**الطريقة:** أجري بحث منهجي باللغة الإنجليزية باستخدام EMBASE، MEDLINE وقواعد بيانات مكتبة كوكرين في كلية طب الأسنان، جامعة الملك عبدالعزيز خلال الفترة ما بين 2004م و 2013م. اختيرت المقالات على أساس معايير الاشتمال المحددة مسبقا. بعد ذلك تم استعراض المرجعية وتحليلها للبيانات ذات الصلة.

**النتائج:** توافقت 11 مقالا مع معايير الاشتمال وجرى مراجعتها وتحليلها. نسبة نجاح منظار الغدد اللعابية جنبا إلى جنب مع الاستئصال الجراحي البسيط للحصوة تتراوح من 69% إلى 100%.

**الخاتمة:** منظار الغدد اللعابية جنبا إلى جنب مع الاستئصال الجراحي البسيط للحصوة هو اجراء آمن وفعال

**Objectives:** To review the available techniques and procedures for management of parotid and submandibular sialoliths with special emphasis on the efficacy and safety of the most commonly used combination of techniques; namely, sialendoscopy with conservative surgical removal of the stone.

**Methods:** A systematic search of the English literature using MEDLINE, EMBASE, and the Cochrane library databases were conducted at the Faculty of Dentistry, King Abdulaziz University, Jeddah, Saudi Arabia. Articles between the years 2004 and 2013 were selected on the basis of preset inclusion criteria. Then, they were reviewed against a checklist to assess the evidence of efficacy of therapy or prevention and analyzed for pertinent data.

**Results:** Eleven articles met the inclusion criteria and were reviewed and analyzed. The success rate of

sialendoscopy combined with minor surgical removal of parotid and submandibular sialoliths ranges from 69-100%.

**Conclusion:** Sialendoscopy combined with a minor surgical extraction of parotid and submandibular sialoliths is safe and efficacious.

*Saudi Med J 2014; Vol. 35 (10): 1188-1194*

*From the Diagnostic Department, Division of Oral and Maxillofacial Radiology, Faculty of Dentistry, King Abdulaziz University, Jeddah, Kingdom of Saudi Arabia.*

*Received 23rd April 2014. Accepted 12th August 2014.*

*Address correspondence and reprint request to: Dr. Fatima M. Jadu, Assistant Professor and Consultant, Diagnostic Department, Division of Oral and Maxillofacial Radiology, Faculty of Dentistry, King Abdulaziz University, PO Box: 80200, Jeddah 21589, Kingdom of Saudi Arabia. Tel. +966 (12) 5400000. Fax. +966 (12) 6952437. E-mail: fjadu@kau.edu.sa*

Obstructive conditions of the salivary glands are a common condition that affects nearly 1% of the general population.<sup>1</sup> Among the causes of obstruction, sialoliths are the most common, accounting for more than 50% of all symptomatic cases.<sup>2</sup> The etiology of sialoliths is not fully understood; however, they are thought to result from the inorganic material buildup around an organic nidus in the duct or less frequently the parenchyma of a salivary gland.<sup>3</sup> When the stone becomes large enough to obstruct the salivary duct, saliva builds up especially during meal times when copious amounts of saliva are rapidly produced.<sup>4</sup> The condition is cyclic and chronic in nature resulting in a low grade chronic inflammatory response in the ducts (sialodochitis) and/or parenchyma (sialadenitis).<sup>4</sup> More importantly, the persistence of the obstruction may predispose the gland to retrograde infections due to saliva stagnation.<sup>4</sup> Retrograde infections lead to acute sialadenitis, which is a painful condition that requires

immediate attention and prescription of appropriate antibiotics.<sup>4</sup>

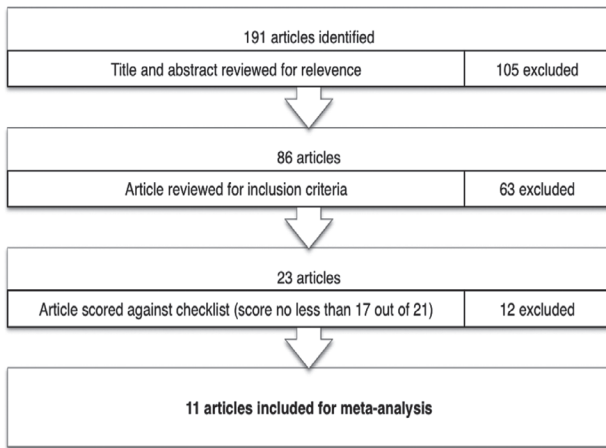
Sialolithiasis most often affects the major salivary glands with the submandibular gland affected more often (80-90%) than the parotid (5-10%).<sup>5</sup> This is likely due to the long, tortuous upward path of the major duct and the nature and consistency of the submandibular gland saliva, which is thicker in consistency, rich in phosphorous and has a high pH that is conducive of stone formation.<sup>6</sup> Sialolithiasis, which has a peak incidence during the fourth to sixth decades of life is reportedly more common in females with a male to female ratio of 3:4.<sup>7</sup> Management of sialoliths in the past involved controlling any acute inflammatory signs and symptoms, and then removing the stone, which more often than not involved complete removal of the gland itself under the pretense that gland function could not be restored after stone removal. Complete removal of the salivary gland usually led to a number of complications, such as xerostomia that significantly alters the quality of life. More recently, it has been proven that gland function can be satisfactory after sialolith removal, which has led to the development of a number of conservative stone removal techniques.<sup>8</sup> These conservative techniques advanced over the past decade to increase the effectiveness of removing salivary obstructions while reducing side effects, but the application has been limited to strictly selected cases where the stones are generally smaller than 7 mm, mobile, and distally located.<sup>9</sup> In 2002, Nahlieli et al<sup>10</sup> demonstrated that combining techniques aids in managing difficult cases that are otherwise, refractory to single conservative techniques. They introduced an endoscopy assisted stone removal technique for the parotid gland that quickly became widely accepted for sialolithotomy of both the parotid and submandibular glands. Intra-oral sialolithotomies are used for both parotid and submandibular stones and involve an extended dissection under endoscopic control.<sup>2</sup> Extra-oral sialolithotomy is reserved for impacted parotid stones and ones that are proximally located.<sup>2</sup> In this article, we will review the available techniques and procedures for management of parotid and submandibular sialoliths with special emphasis on the efficacy and safety of the most commonly used combination of techniques; namely, sialendoscopy with conservative surgical removal of the stone.

**Disclosure.** Authors have no conflict of interests, and the work was not supported or funded by any drug company.

**Methods.** A systematic search of the English literature was conducted using the OVID, MEDLINE, EMBASE, and the Cochrane Library databases and MeSH terms such as: salivary gland calculi/surgery, salivary duct calculi/surgery, salivary calculi/surgery, and endoscopes. Reference lists were searched for further identification of relevant articles. Inclusion criteria for the articles were defined as: 1) Original peer reviewed articles, 2) Combined sialendoscopy with conservative surgical stone extraction for the management of parotid or submandibular sialoliths, and 3) Reported success rates as symptom free and free of residual obstruction. The search was conducted at the Faculty of Dentistry, King Abdulaziz University, and included studies spanning 9 years from 2004 to 2013. The 2 authors independently reviewed the selected articles against the "Checklist to assess evidence of efficacy of therapy or prevention" (Table 1).<sup>11</sup> Disagreement was resolved by consensus. The process of article selection and the review is detailed in Figure 1. Next, the authors extracted the relevant data including the sample size, gland type, success rate, complications and follow up duration.

**Table 1** - Checklist to assess evidence of efficacy of therapy or prevention.<sup>11</sup>

Citation
1. Was the study ethical?
2. Was a strong design used to assess efficacy?
3. Were outcomes (benefits and harms) validly and reliably measured?
4. Were interventions validly and reliably measured?
5. What were the results?
• Was the treatment effect large enough to be clinically important?
• Was the estimate of the treatment effect beyond chance and relatively precise?
• If the findings were "no difference" was the power of the study 80% or better?
6. Are the results of the study valid?
• Was the assignment of patients to treatments randomized
• Were all patients who entered the trial properly accounted for and attributed at its conclusion?
○ Was loss to follow-up less than 20% and balanced between test and controls?
○ Were patients analyzed in the groups to which they were randomized
• Was the study of sufficient duration?
• Were patients, health workers, and study personnel "blind" to treatment?
• Were the groups similar at the start of the trial?
• Aside from the experimental intervention, were the groups treated equally?
• Was care received outside the study identified and controlled for?
7. Will the results help in caring for your patients?
• Were all clinically important outcomes considered?
• Are the likely benefits of treatment worth the potential harms and costs?



**Figure 1** - The stepwise process of selecting, reviewing, and scoring the articles included in the meta-analysis.

Meta-analysis was performed using a random effect model to calculate the pooled success rate. To measure for publication bias, a funnel plot was graphed and the Fail-Safe N and Begg and Mazumdar rank correlation tests were conducted. Heterogeneity between studies was tested using the Q statistic, with the  $\chi^2$  approach. StatsDirect software (StatsDirect Ltd, Cheshire, UK) 2.7.8 was used for the statistical analysis.

**Results.** Eleven studies were included in the meta-analysis. The 11 studies and their results are summarized in Table 2. Success rates ranged from 69-100% even at follow up times of up to 81 months with very few reported complications. The pooled success rate was 92.8% (95% confidence interval, 0.87-0.96) with  $p < 0.001$ . These results are shown in Figure 2 in addition

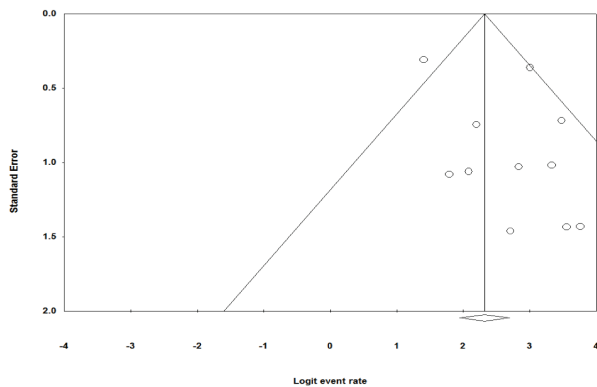
**Table 2** - A summary of the 11 articles included in the meta-analysis and their results.

Author & year	Year	Sample size n	Gland type	Stone size and location	Surgical approach	Success rate n (%)	Complications	Follow up duration (months)
Ziegler et al <sup>25</sup>	2004	17	SM	Range 4-10 mm Hilum	Transmucosal	17/17 (100)	None	Median 19 Range 4-49
McGurk et al <sup>26</sup>	2006	7	Parotid	Mean 11 mm NR	Preauricular	7/7 (100)	Duct ligation (2 pt)	Mean 10 Range 6-18
Marchal <sup>27</sup>	2007	37	Parotid	NR	Transcutaneous classic or face lift type	33/37 (92)	Duct ligation (3 pt) because of polycystic ductal disease (1 pt) mega duct (1 pt) combination (1 pt)	Mean 19
		29	SM	NR	Transmucosal	20/29 (69)	Continuous swelling (8 pt)	Mean 22
Nahlieli et al <sup>24</sup>	2007	41	SM	Mean 7 mm Proximal primary duct	Transmucosal	41/41 (100)	Swelling (7 pt) Bleeding (1 pt)	Range 1-24
		104		Mean 7 mm Hilum		101/104 (97.1)	Temporary lingual nerve paresthesia (1 pt)	
		24		Mean 7 mm Multiple stones in hilum		19/24 (79.1)		
Liu et al <sup>28</sup>	2009	29	1 Parotid	NR	Buccal incision	1/1 (100)	Postop infection (2 pt)	Range 3-30
			28 SM	Range 5-8 mm Hilum, premolar/molar segment of primary duct	Transmucosal	27/28 (96.4)	Ranula (1 pt)	
Walvekar et al <sup>29</sup>	2009	20	6 Parotid 14 SM	Range 5-13 mm, Parotid 5-23 mm SM	Transmucosal	18/20 (90.0)	Minor complications (4 pt)	Range 1-13
Karavidas et al <sup>30</sup>	2010	67	Parotid	Average 7.2 mm Hilum, proximal third, mid third of primary duct	Preauricular (40 pt) Transcutaneous (27 pt)	65/67 (97.0)	Duct perforation (1 pt) Duct ligation (1 pt) Acute parotitis (2 pt) Cheek scar (1 pt)	Median 25 Range 2-81
Koch et al <sup>23</sup>	2010	9	Parotid	Average 8.2 mm Range 5.5-11 mm NR	Transcutaneous	8/9 (88.9)	Irreparable damage to ductal structures (1 pt)	Mean 18.9 Range 4-30
Su et al <sup>31</sup>	2010	18	SM	Median 1.5 mm Range 0.8-2.5 mm Hilum	Transmucosal	17/18 (94.4)	Minor complications (4 pt) Postop infection (1 pt) Temporary tongue numbness (3 pt)	Median 18 Range 1-38
Wallace et al <sup>32</sup>	2010	7	2 Parotid 5 SM	Mean 19 mm Range 15-25 mm Intraglandular (2 pt) Hilum (4 pt) Duct (1 pt)	Transcutaneous for parotid and Transmucosal for SM	6/7 (86.0)	Partial transection of lingual nerve (1 pt)	Mean 1.6 Range 0-6
Kopec et al <sup>3</sup>	2013		SM	NR	Hilar incision	21/21 (100)	NR	Mean 19.6 Range 6-48

SM - submandibular, NR - not reported, pt - patient

Model	Study name	Statistics for each study					Events/Total	Event rate and 95% CI					Weight (Random)		
		Event rate	Lower limit	Upper limit	Z-Value	p-Value		Total	-1.00	-0.50	0.00	0.50	1.00	Relative weight	
	Ziegler, 2004	0.972	0.678	0.998	2.479	0.013	17 / 17							4.13	
	McGurk, 2006	0.938	0.461	0.996	1.854	0.064	7 / 7							4.00	
	Marchal, 2007	0.803	0.690	0.882	4.541	0.000	53 / 66							20.19	
	Nahlieli, 2007a	0.953	0.908	0.976	8.287	0.000	161 / 169							18.87	
	Liu, 2009	0.966	0.792	0.995	3.274	0.001	28 / 29							7.05	
	Walvekar, 2009	0.900	0.676	0.975	2.948	0.003	18 / 20							10.56	
	Karavidas, 2010	0.970	0.888	0.993	4.849	0.000	65 / 67							11.02	
	Koch, 2010	0.889	0.500	0.985	1.961	0.050	8 / 9							6.64	
	Su, 2010	0.944	0.693	0.992	2.753	0.006	17 / 18							6.94	
	Wallace, 2010	0.857	0.419	0.980	1.659	0.097	6 / 7							6.46	
	Kopec, 2013	0.977	0.723	0.999	2.629	0.009	21 / 21							4.15	
	COMBINED	0.928	0.874	0.960	8.031	0.000									

**Figure 2** - Results of the random effect model used for the meta-analysis demonstrating the detailed statistics for each study in addition to the event rate and relative weight.



**Figure 3** - Funnel plot of standard error for the 11 studies included in the meta-analysis demonstrating a relatively symmetrical distribution.

to the event rate (forest plot) and the relative weight for each study.

The funnel plot is shown in **Figure 3** with the 11 chosen studies included in this review relatively symmetrically distributed. The Fail-Safe N is 350 and the Kendall's tau  $\beta$  is -0.11 with a 1-tailed  $p=0.32$ . Both these test results indicate the lack of publication bias. Heterogeneity analysis calculated a Q of 18.3 (df=10) ( $p<0.05$ ) and I<sup>2</sup> (inconsistency) of 45.3% (95% confidence interval, 0.87-0.94), which indicates moderate heterogeneity.

**Discussion.** Management of sialoliths ranges from the conservative gland massage, hydration, and salivary flow stimulation to the more extreme gland removal with many other options now available between these 2 extremes.<sup>12</sup> Choosing the appropriate management option depends on many factors including the size and shape of the sialoliths. Aside from sialolith location and mobility. Other factors to consider are the patient symptoms and the imaging findings that clarify the

amount and degree of permanent damage to the glandular structures. Generally, sialoliths that are larger than 7 mm should not be retrieved conservatively but rather removed.<sup>9</sup> Also, sialoliths that are round or oval are more amenable to conservative retrieval than irregularly shaped ones.<sup>13</sup> Sialolith location is a vital factor in determining management because those that are located in the primary duct especially the distal portion of the duct are more manageable with conservative measures whereas those located at the hilum or within the gland substance require more invasive methods of removal.<sup>9</sup> Preoperative clinical examination and imaging are pivotal in determining the mobility status of sialoliths because the removal of even small sialoliths can become unsuccessful if the stone is not mobile.<sup>9</sup> As a rule, asymptomatic stones should be managed conservatively regardless of their number or size. As mentioned earlier, salivary function usually remains satisfactory after stone removal; however, salivary duct distention is more often than not permanent in nature and may continue to be a source of symptoms for the patient as saliva stagnates in these distended ducts. In these extreme cases, gland removal is indicted despite successful stone removal. Below is a brief account of the more commonly used tactics to manage parotid and submandibular sialoliths.

**Lithotripsy.** Lithotripsy is the fragmentation of a stone within the tissue followed immediately by removal of the fragmented pieces.<sup>14</sup> There are several types of lithotripsy depending on the energy used (electromagnetic, laser, pneumatic) and the approach (extracorporeal and intracorporeal).<sup>14</sup> Currently, only extracorporeal mechanical lithotripsy is used to manage sialoliths because the other forms of lithotripsy are either too expensive or have significant side effects. Despite the popularity of extracorporeal lithotripsy, intracorporeal lithotripsy is gaining in popularity and is the focus of many research groups around the world. Extracorporeal lithotripsy involves repeatedly delivering shock

(compression) waves at supersonic speed; hence, the name extracorporeal shock wave lithotripsy (ESWL).<sup>15</sup> The waves are delivered through a medium (water) that has the same acoustic impedance as biological tissues so that the waves are propagated uninterrupted.<sup>15</sup> When the waves strike a body with different impedance such as a stone, they are reflected as compressive and tensile waves. If these reflected waves exceed the compressive and tensile strength of the stone, the stone starts to break down and fragment.<sup>15</sup> The fragmented pieces are then flushed out using sialogogues or sialography or they are removed conservatively via sialendoscopy.

Extracorporeal shock wave lithotripsy is performed under ultra sound guidance for 2 reasons: to identify the location of the stone and to target the administration of the shock waves to avoid damage to the surrounding tissues.<sup>16</sup> Few, minor, and self-limiting effects have been reported including pain, swelling, bleeding, and cutaneous petechiae.<sup>16</sup> This technique is especially helpful for stones that are larger than 7 mm or those that are immobile.<sup>9</sup> It is also indicated for stones of the hilum and parenchyma with an overall success rate that ranges between 1.1% and 83%.<sup>9</sup> Contraindications to the procedure include patients with pace makers or coagulation disorders and acutely inflamed salivary glands.<sup>9</sup>

**Sialendoscopy.** Sialendoscopy is a minimally invasive technique that allows direct visualization of the salivary ducts of the parotid and submandibular glands. Since its introduction in 1990,<sup>14</sup> this technique has revolutionized the diagnosis and management of obstructive conditions of the salivary glands. With a success rate ranging between 96-98%, it has eliminated the need for many invasive and morbid surgical procedures.<sup>17</sup> The only reported contraindication is acute sialadenitis due to the increased risk of duct perforation.<sup>18</sup>

Sialoscopes range in size and may be rigid or semi rigid. They can be equipped with stone retrieval and stricture dilation contraptions for treatment during exploration.<sup>2</sup> The procedure is especially suited for mobile sialoliths that are smaller than 7 mm as long as they are accessible by the endoscope.<sup>9</sup> Alternatively, sialendoscopy can be combined with ESWL or ductoplasty and it is this ability to combine minimally invasive techniques that has boosted the success rate of these conservative procedures.<sup>19</sup> Pain and swelling are the 2 main side effects, but these are usually minor.<sup>2</sup> Antibiotics may be prescribed after extensive manipulation.

**Gland preserving surgery (ductoplasty).** These are minor surgical procedures that are performed under

local anesthesia or day-care general anesthesia to remove large immobile stones when EWSL is not possible.<sup>20</sup> A small incision is made preferentially transorally, but sometimes it is made transcutaneously for parotid gland sialoliths.<sup>20</sup> The duct continuity is restored following stone removal.<sup>20</sup> Although in some submandibular cases, the duct is marsupialized by suturing its walls to the floor of the mouth instead of restoring the original continuity.<sup>20</sup> Side effects with these types of surgical procedures are rare and there have been no cases of permanent nerve damage reported.<sup>20</sup> Among the reported side effects are pain, transient lingual nerve paresthesia, hemorrhage and ranula formation.<sup>20</sup> Success rates range between 95% for the parotid gland and 92% for the submandibular gland.<sup>20</sup>

**Sialadenectomy.** The procedure of complete gland removal is reserved for symptomatic cases where conservative methods have failed. Capaccio et al<sup>21</sup> detailed the indications for adenectomy as follows: 1) Failure to remove a parotid or submandibular gland stone by conservative methods. 2) Multiple large unilateral or bilateral parenchymal stones with recurrent sialadenitis. 3) Complications during sialendoscopic procedures such as entrapping of the stone retrieval basket. The authors<sup>21</sup> also outlined indications for adenectomy that are not related to sialoliths: 1) Stricture recurrence after conservative balloon ductoplasty. 2) Persistent symptomatic sialadenitis in patients who have Sjogren's syndrome not responding to systemic or local endoscopic steroid lavage. 3) Persistent symptomatic sialadenitis in patients previously treated with <sup>131</sup>I whose condition does not respond to systemic or local therapy.

Parotidectomy procedures may be superficial or complete, usually carried out with the modified blair incision.<sup>22</sup> In either case, every effort is made to preserve the facial nerve branches because one of the most common complications of this procedure is transient or permanent facial nerve damage.<sup>22</sup> Hematoma and seroma are also possible complications of this procedure.<sup>22</sup> Frey syndrome is a late complication that may arise several years after a parotidectomy.<sup>22</sup> The syndrome involves redness and perspiration over the parotid region before meals. This complication arises when severed parasympathetic nerves regenerate in an aberrant fashion and innervate sweat glands in the dermis.<sup>22</sup> The complication can be managed with botulinum toxin A injections, anticholinergic creams and topical antiperspirants.<sup>22</sup> Some degree of facial asymmetry is detected following total parotidectomy but is less noticeable with partial parotidectomy.

Submandibular glad resection is usually carried out through a transcervical approach, although an intra-oral



approach is also possible.<sup>22</sup> In submandibular cases, efforts are made to preserve the marginal mandibular branch of the facial nerve, the lingual nerve, and the hypoglossal nerve.<sup>22</sup> Side effects of this procedure include bleeding, infection, seroma, and nerve damage.<sup>22</sup>

Despite the advances in conservative management of sialoliths, 10-20% of cases are refractory and mandate the removal of the gland.<sup>23</sup> However, combining approaches and techniques are proving helpful in sparing many salivary glands. In the current study, the success rate of combining sialendoscopy with minor surgery was 92.8% with very few reported complications. The largest study by Nahlieli et al<sup>24</sup> conducted in 2007 reported a common complications such as bleeding, swelling, and nerve damage, but all the complications were immediate in onset and transient in nature. Even at 81 months of follow up the only long term complications were duct ligation and scarring.

It is important to note the selection criteria followed by most studies for this particular combined approach because all the extracted stones were larger than 4 mm in largest diameter and most were located in difficult to reach areas such as the proximal part of the main duct or at the hilum of the gland.

An inherent weakness of this review is the heterogeneity of the included studies of instrumentation and level of operator expertise. However, the evidence provided is supportive of sialendoscopy combined with conservative surgery as an efficacious, safe, and gland preserving technique for sialolith removal from the parotid and submandibular glands. Future research should aim to examine the effectiveness of conservative management methods in treating other causes of salivary obstruction such as strictures.

## References

1. Ngu RK, Brown JE, Whaites EJ, Drage NA, Ng SY, Makdissi J. Salivary duct strictures: nature and incidence in benign salivary obstruction. *Dentomaxillofac Radiol* 2007; 36: 63-67.
2. Capaccio P, Torretta S, Ottavian F, Sambataro G, Pignataro L. Modern management of obstructive salivary diseases. *Acta Otorhinolaryngol Ital* 2007; 27: 161-172.
3. Kopeć T, Szyfter W, Wierzbička M. Sialoendoscopy and combined approach for the management of salivary gland stones. *Eur Arch Otorhinolaryngol* 2013; 270: 219-223.
4. Jadu FL, EWN. The mystery of meal time swellings revealed. *Oral Health* 2014; 104: 33-35.
5. Strychowsky JE, Sommer DD, Gupta MK, Cohen N, Nahlieli O. Sialendoscopy for the management of obstructive salivary gland disease: a systematic review and meta-analysis. *Arch Otolaryngol Head Neck Surg* 2012; 138: 541-547.
6. Benson B. In: White SC, Pharoah MJ, editors. *Oral radiology: principles and interpretation*. 7th ed. St. Louis (MO): CV Mosby; 2013. p. 542-561.
7. Buckenham T. Salivary duct intervention. *Semin Intervent Radiol* 2004; 21: 143-148.
8. Su YX, Xu JH, Liao GQ, Zheng GS, Cheng MH, Han L, et al. Salivary gland functional recovery after sialendoscopy. *Laryngoscope* 2009; 119: 646-652.
9. Koch M, Zenk J, Iro H. Algorithms for treatment of salivary gland obstructions. *Otolaryngol Clin North Am* 2009; 42: 1173-1192.
10. Nahlieli O, London D, Zagury A, Eliav E. Combined approach to impacted parotid stones. *J Oral Maxillofac Surg* 2002; 60: 1418-1423.
11. Azarpazhooh A, Mayhall JT, Leake JL. Introducing dental students to evidence-based decisions in dental care. *J Oral Maxillofac Surg* 2002; 60: 1418-1423.
12. Maresch A, Kutler DI, Kacker A. Sialoendoscopy in the diagnosis and management of obstructive sialadenitis. *Laryngoscope* 2011; 121: 495-500.
13. Walvekar RR, Carrau RL, Schaitkin B. Endoscopic sialolith removal: orientation and shape as predictors of success. *Am J Otolaryngol* 2009; 30: 153-156.
14. Turner MD. Sialoendoscopy and salivary gland sparing surgery. *Oral Maxillofac Surg Clin North Am* 2009; 21: 323-329.
15. Zenk J, Koch M, Iro H. Extracorporeal and intracorporeal lithotripsy of salivary gland stones: basic investigations. *Otolaryngol Clin North Am* 2009; 42: 1115-1137.
16. Capaccio P, Torretta S, Pignataro L. Extracorporeal lithotripsy techniques for salivary stones. *Otolaryngol Clin North Am* 2009; 42: 1139-1159.
17. Geithoff UW. Basic sialendoscopy techniques. *Otolaryngol Clin North Am* 2009; 42: 1029-1052.
18. Nahlieli O, Nakar LH, Nazarian Y, Turner MD. Sialoendoscopy: A new approach to salivary gland obstructive pathology. *Journal of the American Dental Association* 2006; 137: 1394-1400.
19. Marchal F. [Salivary gland endoscopy: new limits?]. *Rev Stomatol Chir Maxillofac* 2005; 106: 244-249. French
20. McGurk M, Brown J. Alternatives for the treatment of salivary duct obstruction. *Otolaryngol Clin North Am* 2009; 42: 1073-1085.
21. Capaccio P, Torretta S, Pignataro L. The role of adenectomy for salivary gland obstructions in the era of sialendoscopy and lithotripsy. *Otolaryngol Clin North Am* 2009; 42: 1161-1171.
22. Hsu AK, Kutler DI. Indications, techniques, and complications of major salivary gland extirpation. *Oral Maxillofac Surg Clin North Am* 2009; 21: 313-321.
23. Koch M, Bozzato A, Iro H, Zenk J. Combined endoscopic and transcuteaneous approach for parotid gland sialolithiasis: indications, technique, and results. *Otolaryngol Head Neck Surg* 2010; 142: 98-103.
24. Nahlieli O, Shacham R, Zagury A, Bar T, Yoffe B. The ductal stretching technique: an endoscopic-assisted technique for removal of submandibular stones. *Laryngoscope* 2007; 117: 1031-1035.
25. Ziegler CM, Steveling H, Seubert M, Muhling J. Endoscopy: a minimally invasive procedure for diagnosis and treatment of diseases of the salivary glands. Six years of practical experience. *Br J Oral Maxillofac Surg*. 2004; 42: 1-7.
26. McGurk M, MacBean AD, Fan KF, Sproat C, Darwish C. Endoscopically assisted operative retrieval of parotid stones. *Br J Oral Maxillofac Surg* 2006; 44: 157-160.
27. Marchal F. A combined endoscopic and external approach for extraction of large stones with preservation of parotid and submandibular glands. *Laryngoscope* 2007; 117: 373-377.

28. Liu DG, Zhang ZY, Zhang Y, Zhang L, Yu GY. Diagnosis and management of sialolithiasis with a semirigid endoscope. *Oral Surg Oral Med Oral Pathol Oral Radiol Endod* 2009; 108: 9-14.
29. Walvekar RR, Bomeli SR, Carrau RL, Schaitkin B. Combined approach technique for the management of large salivary stones. *Laryngoscope* 2009; 119: 1125-1129.
30. Karavidas K, Nahlieli O, Fritsch M, McGurk M. Minimal surgery for parotid stones: a 7-year endoscopic experience. *Int J Oral Maxillofac Surg* 2010; 39: 1-4.
31. Su YX, Liao GQ, Zheng GS, Liu HC, Liang YJ, Ou DM. Sialoendoscopically assisted open sialolithectomy for removal of large submandibular hilar calculi. *J Oral Maxillofac Surg* 2010; 68: 68-73.
32. Wallace E, Tauzin M, Hagan J, Schaitkin B, Walvekar RR. Management of giant sialoliths: review of the literature and preliminary experience with interventional sialendoscopy. *Laryngoscope* 2010; 120: 1974-1978.

#### Related Articles

Al-Naami MY, Guraya SY, Arafah MM, Al-Zobydi AH, Al-Tuwaijri TA. Clinicopathological pattern of malignant parotid gland tumors in Saudi Arabia. *Saudi Med J* 2008; 29: 413-417.

Take G, Ilgaz C, Erdogan D, Ozogul C, Elmas C. A comparative study of the ultrastructure of submandibular, parotid and exocrine pancreas in diabetes and fasting. *Saudi Med J* 2007; 28: 28-35.

Al-Arfaj AA, Arora RK, El Hassan AY, Al-Metwalli RR. Lipomatosis of the parotid gland in children. *Saudi Med J* 2003; 24: 898-900.