

Primary Breast Tuberculosis

Abdulahleem A. Noorwali, FRCS(I), SSC-GC

*Department of Surgery, Faculty of Medicine
King Abdulaziz University
Jeddah, Saudi Arabia
anoorwali22@hotmail.com*

Abstract. Primary tuberculosis of the breast is a rare disease and differential diagnosis with other benign and malignant disease of the breast can be difficult with imaging methods. Although tuberculosis is a very common disease in endemic areas, any form of tuberculosis mastitis may present with features of malignancy. Diagnosis based mainly on the identification of tubercle bacilli. A case presented of an 82-years-old woman, complaining of three lumps in right breast tail with no previous history of the disease, diagnosed as primary tuberculosis in the breast after microbiological analysis with acid-fast bacilli. It was difficult to be diagnosed and differentiated from breast cancer by radiological or histopathological tools.

Keywords: Breast cancer, Breast abscess, Breast tuberculosis, Breast chronic mastitis.

Introduction

Tuberculosis (TB) is a chronic granulomatous disease caused by *Mycobacterium tuberculosis*^[1] and breast tuberculosis, which is a rare pathology, is having a very low incidence ranging from 0.1-0.5%^[2]. Breast tuberculosis commonly affects women in reproductive ages, usually between 20 and 40 years. This is seldom encountering prepubescent females and on an elderly woman^[3]. This disease may be of primary etiology when breast infection affects breast solely, or may result from other foci in the body, which is termed as the secondary tuberculosis of breast^[4].

Correspondence & reprint request to:

Dr. Abdulhaleem A. Noorwali
P.O. Box 14785, Jeddah 21434, Saudi Arabia

Accepted for publication: 07 January 2012. Received: 30 October 2011.

Breast tuberculosis is misdiagnosed as carcinoma or pyogenic abscess, both clinically as well as radiologically, especially if well-defined clinical features are absent. Therefore, diagnosis of breast tuberculosis remains a challenge for clinicians and requires a high degree of suspicion. Fine needle aspiration cytology for identification of the Acid Fast Bacilli (AFB) is required for proper diagnosis^[5].

Case Report

An 82-years-old female patient admitted to our surgical department through OPD. The patient was complaining of three masses in the right breast tail for three months duration. Two months prior to the presentation, one of the lumps showed slight increase in size associated with throbbing pain and spontaneous whitish discharge. The patient has no history of any chronic medical or surgical illness and her family history was clear.

The findings at physical examination showed normal vital signs and three mildly tender lumps in the right breast tail ranging in size from 2-4 cm, associated with hotness and redness. The lumps were not fixed to skin or chest wall; however, there was an area of fluctuation within the lumps. Otherwise, the lumps were firm with no opening sinuses neither lymphadenopathy (Fig. 1). Examination of the contra lateral breast was unremarkable.

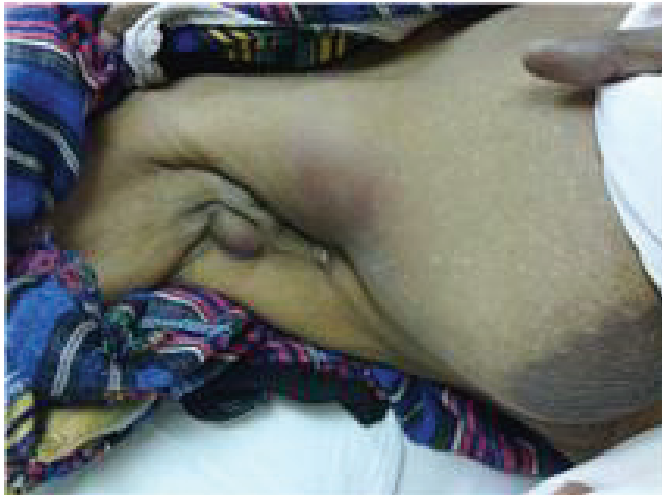

Fig. 1. Picture of right breast tail showing three lumps ranging in size 4-2 cm, associated with redness of the largest (4 x 3) cm mass.

The patient was admitted and had a bilateral breast mammogram. The mammogram showed that both breast parenchyma predominantly fatty, with evidence of increased density in the right breast tail with thickening and an edema of the nearby breast mixed parenchyma. There was no evidence of micro calcifications (Fig. 2). Target ultrasonography of the right breast tail was showing irregular mixed echogenicity, mainly hypoechoic collection in keeping with forming abscess measures 5x3 cm. In the axilla there was a tiny an echoic area seen superiorly (Fig. 3). CT

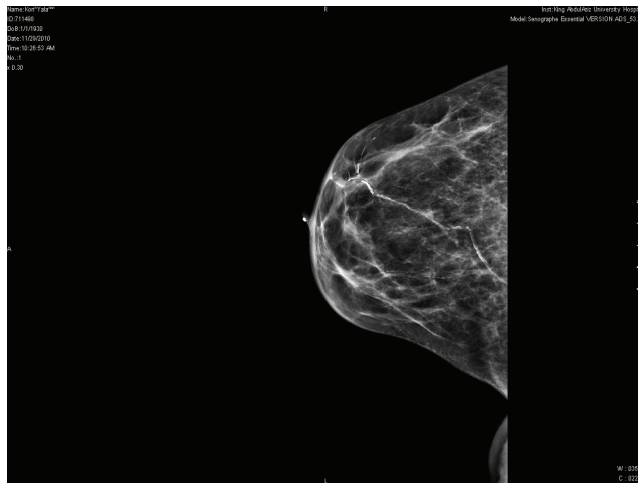

Fig. 2. Mammography of right breast showing increased density in the breast tail with thickening and edema of the nearby breast mixed parenchyma.

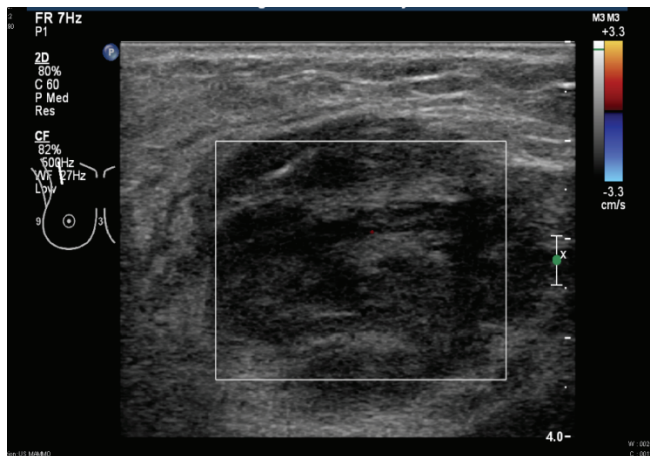


Fig. 3. Ultrasound of right breast and axilla showing hypoechoic collection with a forming abscess.

chest showed that there was a heterogeneous 5 cm solid mass above the mid portion of the right pectoralis major muscle, with minimal fat stranding and elevating the over lying skin. The low attenuation areas within the mass are likely to be necrotic. The mass was most likely inflammatory with no evidence of skin or deep pectoralis fascia invasion.

Laboratory investigation showed that, the C-reactive proteins (CRP) was 41.7; erythrocyte sedimentation rate (ESR) was high at 25 mm/ h, WBC 15 k/uL, neutrophils 87%, and lymphocyte 55%. True cut biopsy was taken and it revealed necrotic tissue. The patient was taken to the operation room for open biopsy, and for incision and drainage of the abscess.

Intra operatively, there were whitish thick cheesy material found and sent for Ziehl-Neelsen (ZN) stain, tuberculosis culture and bacterial culture. Molecular mycobacterium tuberculosis and polymer chain reactions (PCR) were negative. The acid fast bacilli test was positive (+2) and TB culture revealed isolation of mycobacterium TB complex, which was positive and sensitive to anti-tuberculosis therapy. Histopathology was difficult, and only showed an acute inflammation with neutrophils and lymphocytes. There was no evidence of epithelioid granulomas, Langerhans' cell nor caseation necrosis. The full examination of the patient (X-ray, CT) revealed that there was no tuberculosis anywhere else; which indicated that the breast tuberculosis was primary.

The patient was referred to the infectious disease team. She received Isoniazid (INH) 300 mg, Rifampin 600 mg and Vitamin B6 40 mg for 9 months. Pyrazinamide 1 g, and Ethambutol 600 mg was administered for two months. Regular follow up of the case showed dramatic improvement during the treatment course. There was no recurrence for one year of follow up.

Discussion

Breast tuberculosis is common in endemic areas, and about 3-4.5% in non-endemic countries^[6,7]. Tuberculosis is caused by the acid-fast bacillus (*Mycobacterium tuberculosis*), so it may involve any organ in the body. However, some organs or tissues like the breast skeletal muscles and spleen are usually resistant to tuberculosis. Therefore, tuberculous mastitis is an uncommon disease^[8].

Risk factors of breast TB disease are multiparty, lactation, trauma, past history of suppurative mastitis, immune compromised patient, AIDS, direct extension from contiguous structure and low socio economic patients^[9].

Breast tuberculosis is classified as primary and as secondary form. In the primary form, the only location of the disease is the breast, where infection may spread by hematogenous or direct extension occurs by contact of infected material with abrasion or irritated skin or breast ducts, during pregnancy and lactation period. Secondary form is about 3% of all breast diseases. It is more frequent and a previous history of tuberculosis exists in these cases. The main routs of spread are either from axillary lymph node through retrograde lymphatic ducts, dissemination *via* direct extension from lung and pleura, or hematogenous spread^[10].

In the present case, the patient did not have any focus of tuberculosis outside the breast nor lymphadenopathy, and there was no primary attack of tuberculosis either on physical or radiological examination. Therefore, it was diagnosed as a primary form of disease.

Most of breast tuberculosis patient are presented with a lump, ulcer and/or breast abscess that may be associated with nipple retention, discharging sinuses and fistula in advanced disease or after needle puncture^[11].

Tuberculosis of the breast is a condition that is difficult in differentiation from other benign or malignant conditions. In the absence of well-defined clinical features, the nature of the disease remains obscured and it is often mimics for carcinoma or pyogenic breast abscess. Mammographic findings are not always specific and accurate, for breast tuberculosis, which can be misdiagnosed as adenocarcinoma of the breast (inflammatory and scirrhous type). The two mammographic findings that are specific for breast tuberculosis are "skin bulge" and "sinus tract site"^[11].

Ultrasonography reveals hypoechoic fluid containing masses with internally floating and echogenic material in the breast parenchyma, or retro - mammary region in tuberculosis breast^[11], which was observed in the present case. In addition to that, CT scan is found to be useful in differentiation between primary and secondary breast tuberculosis^[11].

Diagnosis of the disease needs cytological evidence of epithelioid granulomas, Langerhans' giant cell, lymphocytic aggregation and caseation material. Furthermore, to confirm the diagnosis, Acid Fast Bacilli or tissue culture for tuberculosis are required to be positive^[12], which was found in the present case as +2 AFB. The accuracy of fine needle aspiration (FNA) in diagnoses of breast tuberculosis varies from 73%-100%, and tissue culture is found to be positive in 25-30% of cases^[12]. For difficult cases, tissue biopsy is needed and excision biopsy of the breast is avoided.

After confirmed diagnosis of breast tuberculosis, patient should start anti-tubercular therapy, with four drugs as first line of treatment. Surgical intervention is required for abscesses and excision of sinuses and masses. In resistant cases, simple mastectomy should be performed^[11].

Conclusion

Primary breast tuberculosis is an uncommon breast pathology, which usually misdiagnosed as pyogenic abscess or carcinoma, especially with clinical and mammographic feature. Excluding carcinoma via FNA, under ultrasonography guide is the best method for establishing diagnosis and avoids unnecessary excision biopsy. However, microbiological and histological examinations remain the gold standard method to confirm the diagnosis of this condition.

The disease is eminently curable with the modern anti-tubercular therapy, and with or without minimal surgical intervention.

References

- [1] **Kervancioğlu S, Kervancioğlu R, Ozkur A, Sirikçi A.** Primary tuberculosis of the breast. *Diagn Interv Radiol* 2005; **11**(4): 210-212.
- [2] **Madhusudhan KS, Gamangatti S.** Primary breast tuberculosis masquerading as carcinoma. *Singapore Med J* 2008; **49**(1): e3-5.
- [3] **Filippou DC, Rizos S, Nissoitis A.** Primary breast tuberculosis. A case report. *Radio-Oncol* 2003; **37**(1): 1-3.
- [4] **D'Orsi CJ, Feldhaus L, Sonnenfeld M.** Unusual lesions of the breast. A case report. *Acta Radiol* 2000; **41**: 613.
- [5] **Wani I, Lone AM, Malik R, Wani KA, Wani RA, Hussain I, Thakur N, Snabe V.** Secondary tuberculosis of breast: case report. *ISRN Surg* 2011; 2011: 529368.
- [6] **Maroulis I, Spyropoulos C, Zolota V, Tzorakoleftherakis E.** Mammary tuberculosis mimicking breast cancer: a case report. *J Med Case Reports* 2008; **2**: 34.

- [7] **Gupta R, Gupta AS, Duggal N.** Tuberculosis mastitis. *Int Surg* 1982; **67**(4 Suppl): 422-424.
- [8] **Hamit HF, Ragsdale TH.** Mammary tuberculosis. *J R Soc Med* 1982; **75**(10): 764-765.
- [9] **Yuen JHF, Lam TPW, Leong L.** Primary tuberculosis of the breast. *J HK Coll Radiol* 2003; **6**: 33-35.
- [10] **Hale JA, Peters GN, Cheek JH.** Tuberculosis of the breast; rare but still existent. Review of the literature and report of an additional case. *Am J Surg* 1985; **150**(5): 620-624.
- [11] **Tewari M, Shukla HS.** Breast tuberculosis: diagnosis, clinical features and management. *Indian J Med Res* 2005; **122**(2): 103-110
- [12] **Kakkar S, Kapila K, Singh MK, Verma K.** Tuberculosis of the breast: Acytophologic study. *Acta Cytol* 2000; **44**(3): 292-296.

تقرير عن حالة

عبدالحليم أحمد نورولى

قسم الجراحة ، كلية الطب ، جامعة الملك عبد العزيز

جدة - المملكة العربية السعودية

المستخلص. السل الابتدائي في الثدي هو مرض نادر جداً والتشخيص التفريقي مع غيره من الأمراض الحميدة والخبيثة للثدي يكون صعباً حتى مع أساليب التصوير والتشخيص الحديثة. على الرغم من أن مرض السل هو مرض شائع جداً في المناطق الموبوءة، ويأتي التهاب السل الضرعى بأى شكل من أشكال الالتهابات والأورام الحميدة وأحياناً الأورام الخبيثة للثدي. يستند التشخيص أساساً على تحديد العصيات السلية. كما في حالة السيدة وعمرها ٨٢ عاماً التي كانت تعاني من ثلاث كتل في الإبط الأيمن، مع عدم وجود تاريخ سابق من هذا المرض، وقد تم تشخيص مرض السل الابتدائي في الثدي بعد التشخيص الميكروبيولوجي للأنسجة وكذلك مع اختبار البكتيريا بالحمض السريع (AFB)، وكان من الصعب تشخيص المرض بواسطة الميكروسكوب أو التصوير الشعاعي للثدي أو الموجات فوق الصوتية لتمييزها عن سرطان الثدي.